



Role of Endothelial Dysfunction and Arterial Stiffness in the Development of Diabetic Retinopathy

Diabetes Care 2015;38:e9–e10 | DOI: 10.2337/dc14-1741

Gerasimos Siasos,^{1,2}
 Nikolaos Gouliopoulos,^{1,3}
 Marilita M. Moschos,³
 Evangelos Oikonomou,¹
 Christina Kollia,¹ Theodosia Konsola,¹
 Dimitrios Athanasiou,¹
 Georgia Siasou,^{1,3}
 Konstantinos Mourouzis,¹
 Konstantinos Zisimos,¹
 Athanasios G. Papavassiliou,²
 Christodoulos Stefanadis,¹ and
 Dimitris Tousoulis¹

Diabetic retinopathy (DR) remains one of the most important diabetic microvascular complications and a leading cause of irreversible blindness, highlighting the importance of close monitoring. The atherosclerotic progression in patients with insulin resistance is precipitated by endothelial dysfunction and vascular impairment (1). Therefore, we examined the association of endothelial dysfunction and arterial stiffness with DR and how these measurements can be used for the early identification and monitoring of patients at high risk to develop DR.

In this case-control study, we included 100 healthy control (CL) subjects and 200 consecutive subjects with type 2 diabetes recruited from the 1st Department of Ophthalmology of the University of Athens Medical School where they were referred to evaluate for DR. All participants underwent a complete ophthalmological examination by the same experienced ophthalmologist, which included funduscopy after pupillary dilation, fluorescein angiography, and colorful fundus photographs. The diabetic patients, according to the Early Treatment Diabetic Retinopathy Study (ETDRS) classification, were categorized into three groups: 1) no DR (NDR) (108 subjects), 2) background DR (BDR) (78 subjects), and 3) proliferative DR (PDR) (14 subjects).

Endothelial function was evaluated by flow-mediated dilation (FMD) in the brachial artery, and carotid-femoral pulse wave velocity (PWV) and augmentation index (AIx) of the radial artery were measured to evaluate arterial stiffness and reflected waves, respectively, as previously described (2). Several biochemical characteristics including HbA_{1c} were measured in the study population.

Subjects with PDR compared with BDR, NDR, and CL were older, had impaired creatinine clearance, were under insulin treatment more often, had longer duration of diabetes, had earlier onset of the disease, and had increased levels of HbA_{1c} ($P < 0.001$ for all).

Subjects with PDR compared with BDR, NDR, and CL had impaired FMD ($3.38 \pm 1.23\%$ vs. $3.58 \pm 1.24\%$ vs. $5.71 \pm 1.92\%$ vs. $7.54 \pm 3.06\%$, respectively, $P < 0.001$), PWV (10.18 ± 1.86 m/s vs. 11.22 ± 2.86 m/s vs. 9.16 ± 1.97 m/s vs. 8.41 ± 1.75 m/s, respectively, $P < 0.001$), and AIx ($26.27 \pm 9.54\%$ vs. $28.15 \pm 7.92\%$ vs. $24.12 \pm 7.96\%$ vs. $22.52 \pm 8.00\%$, respectively, $P < 0.001$), even after adjustment for multiple confounders such as age, sex, BMI, creatinine clearance, presence of hypertension, dyslipidemia, and smoking habits ($P < 0.001$) (Fig. 1).

In diabetic subjects, multinomial logistic regression analysis after adjustment for the aforementioned confounders as

well as for insulin treatment, duration of the disease, and HbA_{1c} revealed that impaired FMD was an independent predictor of both BDR (odds ratio 0.17, 95% CI 0.08–0.38, $P < 0.001$) and PDR (0.30, 0.10–0.85, $P = 0.03$).

Among diabetic subjects, receiver operating characteristics analysis revealed that FMD has sufficient discriminate ability to detect PDR (area under the curve 0.72, 95% CI 0.59–0.85, $P = 0.006$). Importantly, the negative predictive value of an FMD above 3.22% was estimated at 82%.

Long-term diabetes causes structural and compositional changes and thickening of ocular basement membranes (3). Furthermore, in DR, retinal capillaries are functionally and anatomically incompetent and characterized by increased vascular permeability and impaired autoregulation of blood flow and vascular tone (4). Microvascular disorders in retina, including DR, have been associated with cardiovascular disease (5), highlighting the close relationship of microvascular abnormalities with atherosclerosis.

In the current study, we found a significant association between DR and vascular dysfunction, indicating that these conditions coexist in diabetic patients. Importantly, the progression of the disease and the development of microvascular complications, such as PDR, were strongly associated with further deterioration of

¹1st Cardiology Department, University of Athens Medical School, Hippokraton Hospital, Athens, Greece

²Department of Biological Chemistry, University of Athens Medical School, Athens, Greece

³1st Department of Ophthalmology, University of Athens Medical School, Athens, Greece

Corresponding author: Gerasimos Siasos, gsiasos@med.uoa.gr.

G.S. and N.G. equally contributed to this study.

© 2015 by the American Diabetes Association. Readers may use this article as long as the work is properly cited, the use is educational and not for profit, and the work is not altered.

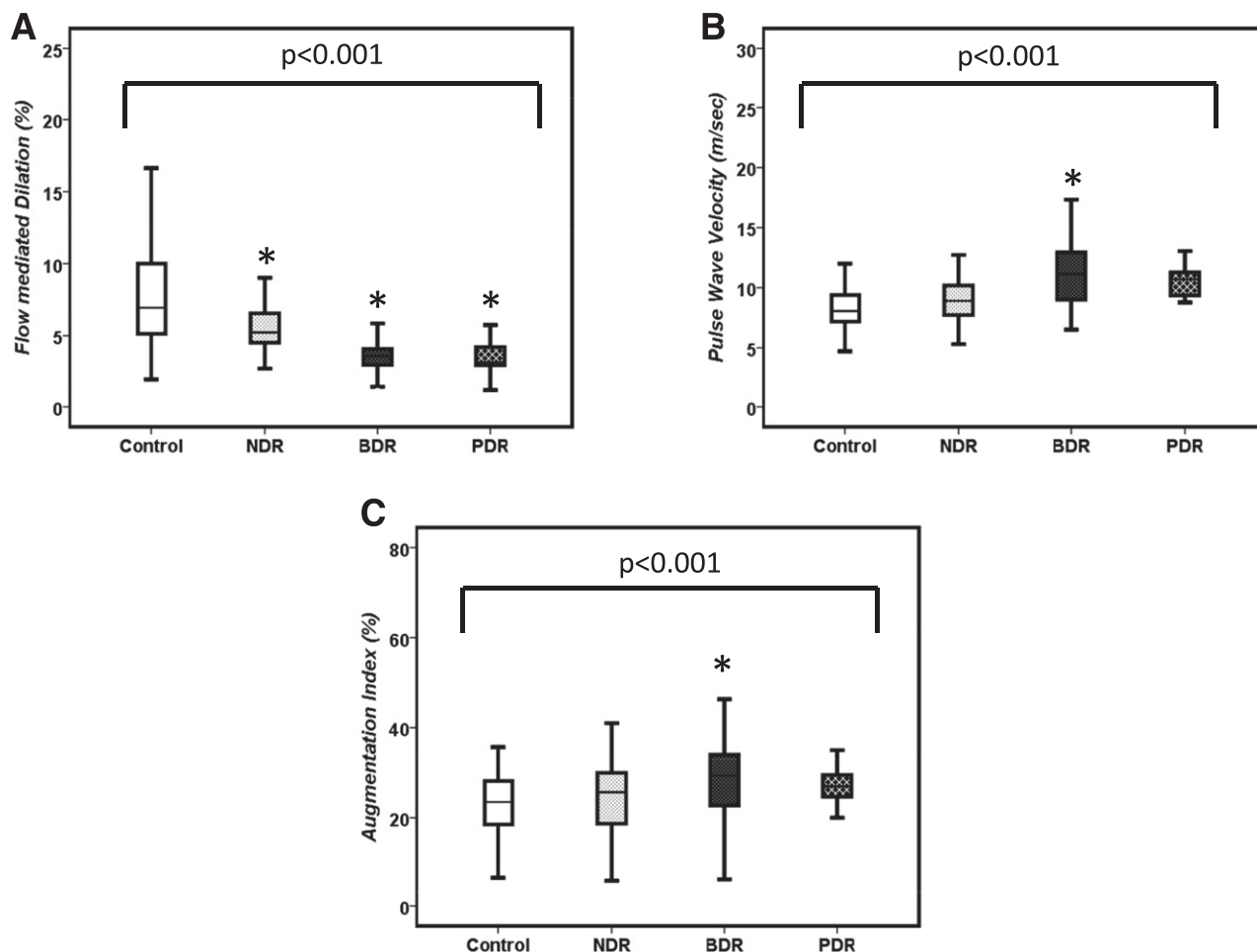


Figure 1—Box plots representing the change in FMD (A), PWV (B), and in AIx (C) for CL (control) and patients with NDR, BDR, and PDR. * $P < 0.05$ compared with CL subjects.

endothelial function and arterial stiffness. These findings highlight the importance of monitoring endothelial function in these patients to avert irreversible microvascular complications. Moreover, it provides further pathophysiological connections concerning the association of endothelial dysfunction and arterial wall impairment with atherosclerosis and complications of diabetes, which can be used to design and study new treatment in cases of DR. Finally, we documented the negative predictive value of endothelial function for the presence of ocular lesions in diabetic subjects.

Duality of Interest. No potential conflicts of interest relevant to this article were reported.

Author Contributions. G. Siasos and N.G. researched data, designed the study, and wrote the manuscript. M.M.M. and D.T. designed the study and reviewed the manuscript. E.O. analyzed the data and wrote the manuscript. C.K., T.K., D.A., G. Siasou, K.M., and K.Z. researched data. A.G.P. and C.S. designed the study and reviewed the manuscript. G. Siasos is the guarantor of this work and, as such, had full access to all the data in the study and takes responsibility for the integrity of the data and the accuracy of the data analysis.

Prior Presentation. Preliminary results of this study were presented at European Society of Cardiology Congress 2014, Barcelona, Spain, 30 August–3 September 2014.

References

1. Tousoulis D, Papageorgiou N, Androulakis E, et al. Diabetes mellitus-associated vascular impairment: novel circulating biomarkers and

therapeutic approaches. *J Am Coll Cardiol* 2013;62:667–676

2. Siasos G, Tousoulis D, Oikonomou E, et al. Effects of omega-3 fatty acids on endothelial function, arterial wall properties, inflammatory and fibrinolytic status in smokers: a cross over study. *Int J Cardiol* 2013;166:340–346

3. Roy S, Ha J, Trudeau K, Beglova E. Vascular basement membrane thickening in diabetic retinopathy. *Curr Eye Res* 2010;35:1045–1056

4. Nair BM, Viswanathan V, Snehalatha C, Mohan RS, Ramachandran A. Flow mediated dilatation and carotid intimal media thickness in South Indian type 2 diabetic subjects. *Diabetes Res Clin Pract* 2004;65:13–19

5. Gerstein HC, Ambrosius WT, Danis R, et al.; ACCORD Study Group. Diabetic retinopathy, its progression, and incident cardiovascular events in the ACCORD trial. *Diabetes Care* 2013;36:1266–1271